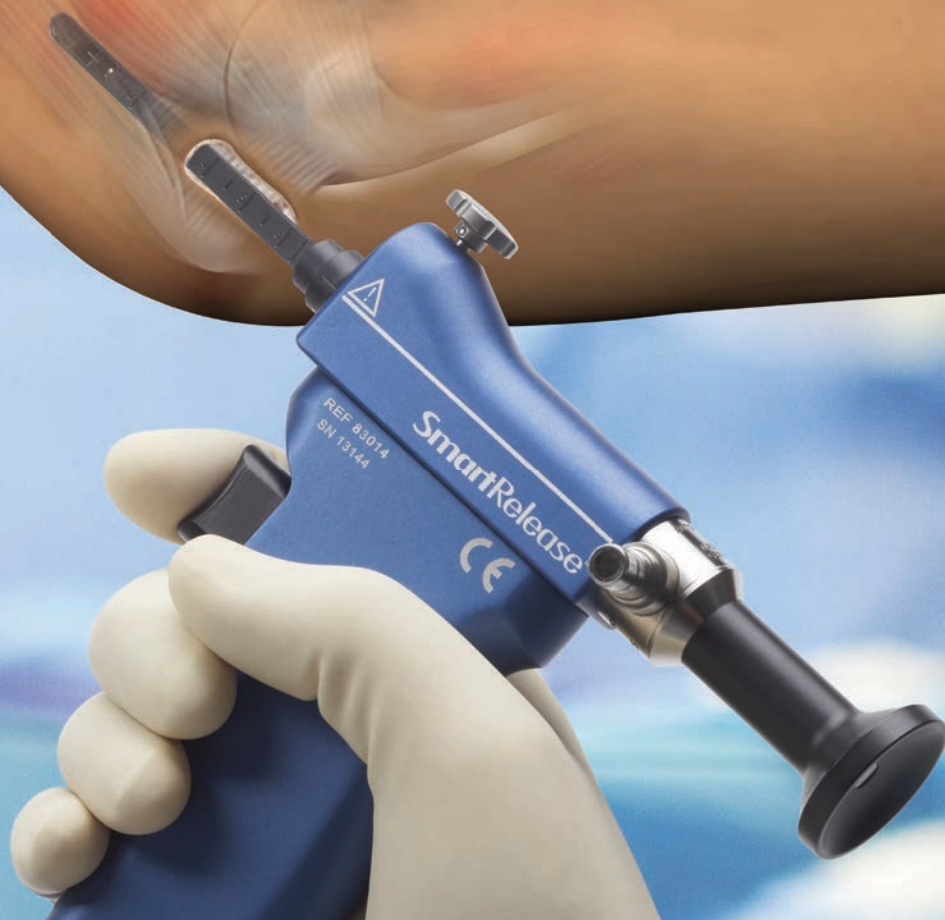

SmartRelease®

Endoscopic Cubital Tunnel



MICROAIRE®
For Surgery. For Life.™

Endoscopic Cubital Tunnel Release Surgical Technique

Introduction

This Surgical Technique is provided as an educational tool and clinical aid to assist medical professionals in the proper protocol for the MicroAire® SmartRelease® Endoscopic Cubital Tunnel Instrumentation. For effective use, surgeons must possess a thorough knowledge and understanding of elbow anatomy and the endoscopic technique using the MicroAire SmartRelease System. Instructional videos and cadaver workshops are available through MicroAire Surgical Instruments.

Those considering using the MicroAire SmartRelease System* should only do so after successfully completing MicroAire's surgical training as well as the relevant training mandated in the professional guidelines of any pertinent hospital, institution or society. For training dates and locations, visit www.microaire.com.

Failure to follow the Surgical Technique may result in permanent injury to the patient. If, while performing this technique, any problems should arise, such as anatomical anomalies, inadequate visualization, inability to identify anatomy or questions concerning technique or instrumentation, the surgeon should abandon the endoscopic cubital tunnel release and convert to another cubital tunnel release procedure.

These pages are not intended to provide medical advice or physician instruction on the appropriate use of products produced or supplied by MicroAire Surgical Instruments, its affiliates, related companies, or its licensors or other partners.

System Description and Intended Use

Indications for Use

The MicroAire® SmartRelease® Endoscopic Soft Tissue Release System is indicated for use in minimally invasive ligament or fascia release:

- Carpal tunnel release in the wrist
- Cubital tunnel release in the elbow

The MicroAire SmartRelease Endoscopic Cubital Tunnel System is comprised of an endoscope and a handpiece that holds a disposable blade assembly. The cubital tunnel device attaches to any standard video camera and light source used in endoscopic procedures. The surgeon introduces the disposable blade assembly into the cubital tunnel through a 3 cm longitudinal incision between the medial epicondyle and olecranon. Viewing the roof of the cubital tunnel fascia through a window at the tip of the instrument, the surgeon elevates the blade to cut the fascia as the instrument is withdrawn.

Indications

The MicroAire SmartRelease Endoscopic Cubital Tunnel System is indicated for patients diagnosed with cubital tunnel syndrome that is not associated with, nor secondary to, any other known pathology (i.e., idiopathic cubital syndrome). Preoperative X-rays of the elbow are strongly recommended to aid in the diagnosis of the associated pathology such as calcific tendinitis and occult fractures. This device is indicated for releasing the distal upper arm enveloping fascia, Osborne's ligament and proximal pronator mass fascia.

Contraindications

The MicroAire Endoscopic Cubital Tunnel Release System is not intended for use in patients with known abnormalities of their elbow (Cubital tunnel), including deformities, rheumatoid and other synovitis. Patients with known abnormalities of the elbow affecting the cubital tunnel, including elbow deformities, severe medial epicondylitis, rheumatoid, bursitis, or other inflammatory diseases of the elbow, have not been studied and are contraindicated. Patients with congenital anatomical abnormalities, particularly those with abnormalities of the medial elbow and subluxation of the ulnar nerve are contraindicated. Patients with smaller elbows or an unusually tight cubital tunnel are also contraindicated.

Warnings

- The surgeon is specifically advised not to use the instrument to explore and/or treat any structure other than the distal upper arm enveloping fascia, Osborne's ligament and proximal pronator mass fascia compressing the course of the ulnar nerve at the cubital tunnel within, or outside of, the cubital tunnel. Failure to heed this warning can lead to damage to the ulnar nerve, median nerve, medial antebrachial cutaneous nerve, flexor-pronator origin, or vascular structures.
- If the surgeon is unable to clearly visualize the undersurface of the fascia with the endoscope without crossing nerve structures, the blade assembly should be withdrawn and the procedure should be converted to a conventional open cubital tunnel release.
- If the Disposable Blade Assembly fails to retract while in the cubital tunnel, release the blade lock screw and separate the Disposable Blade Assembly from the SmartRelease handpiece leaving Disposable Blade Assembly in the cubital tunnel. If blade is still extended, do not remove from cubital tunnel; convert to open procedure.
- Failure to follow the proper training and surgical technique provided in this surgical technique guide can result in permanent injury to the patient. Endoscopic release of the cubital tunnel using the MicroAire SmartRelease Cubital Tunnel System should not be attempted until the surgeon has been trained at a MicroAire-sponsored workshop or approved training. This training requires becoming thoroughly familiar with the Surgical Technique and gaining hands on experience with a trained surgeon who is experienced with the device. The procedure should be performed on cadaveric specimens before initial use. Operating room staff should thoroughly review the MicroAire SmartRelease System Instructions for Use (REF: IM-STRELEASE) prior to setup of this system.

Definitions

- NOTE: Indicates the easiest means of carrying out techniques.
- CAUTION: Indicates special procedures or precautions that must be followed to avoid damaging the system instrumentation.
- WARNING: Indicates that the safety of the patient and hospital personnel could be involved.

Review full list of Notes, Cautions, and Warnings in the Instructions for Use (IM-STRELEASE).

*The MicroAire SmartRelease Endoscopic Cubital Tunnel System uses a dry procedure. No fluid or gas should be introduced into the cubital tunnel during this procedure.

Table of Contents

Instrumentation	3
Troubleshooting Guide for Endoscope Fogging	4
Surgical Setup	5
Operative Technique	6–10
Anesthesia	6
Anatomical Landmarks	6
Making the Incision	6
Preparing a Path for the Instrument	7
Introducing the Blade Assembly into the Cubital Tunnel	8
Releasing the Proximal Fascia	9
Inspecting the Incised Fascia	9
Releasing the Forearm Fascia	10
Assessment of Adequate Release.	10
Closing and Dressing the Wound.	10

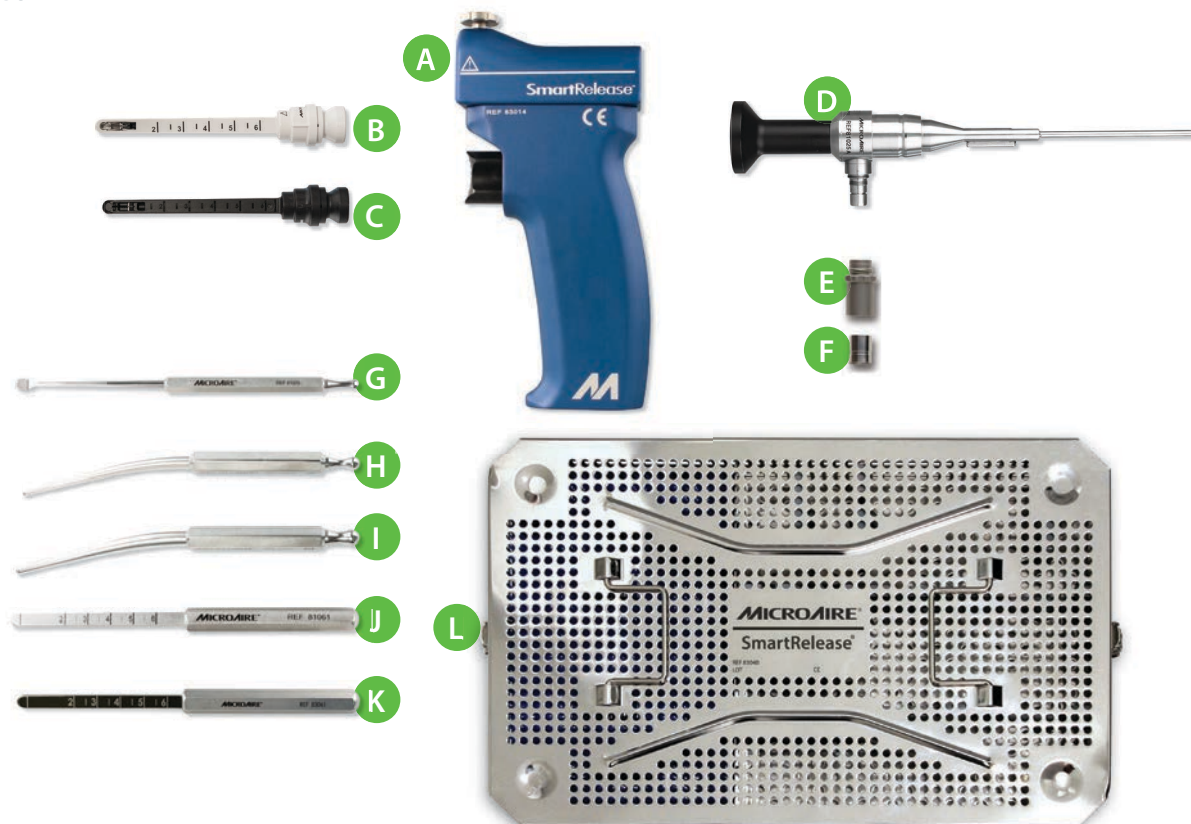


Instrumentation

SmartRelease® Instruments and Accessories

A	SmartRelease Aluminum Handpiece	REF 83014
B	Disposable Standard Blade Assembly	REF 81010-1 or 81010-6
C	Disposable Onyx™ Blade Assembly	REF 83030-1 or 83030-6
D	2.9mm Eyepiece Autoclavable Endoscope	REF 81025
E	Endoscope Light Post Adapter, Storz®/Olympus®	REF 81151
F	Endoscope Light Post Adapter, Wolf®/Dyonics®	REF 81152
G	Elevator	REF 81029
H	Dilator – Small	REF 81026
I	Dilator – Medium	REF 81027
J	Dilator – Coequal to Standard Blade Assembly	REF 81061
K	Dilator - Coequal to Onyx™ Blade Assembly	REF 83061
L	Instrument Sterilization Tray	REF 83040

FIGURE I



For additional information, consult the MicroAire Instructions for Use (REF: IM-STRELEASE)

Troubleshooting Guide for Endoscope Fogging

In order to quickly identify the source of the fogging problem and formulate the appropriate solution, you should:

1. Assemble the system before the surgeon makes the skin incision to start the procedure.
2. Turn on the camera, light source and monitor. White balance using a white sponge and then lay a blue or green towel on the window using the fabric of the towel to set the light intensity and to focus on the mid and distant portion of the window.
3. Observe for any sign of fogging.

NOTE: Beware of contamination caused by disassembling the camera and the endoscope in the sterile field.

Condition	Cause	Solution	Prevention
Fogging— before insertion into surgical site	Moisture inside camera coupler and endoscope lens interface. A single drop of moisture can cause fogging at this juncture.	Disassemble and thoroughly dry endoscope lens and camera coupler interface with alcohol or anti-fog agent and sterile cotton swab.	Pre-warm system by connecting light source and camera before surgeon makes the skin incision. Use anti-fog agent to dry before assembly. Thoroughly dry endoscope lens and camera coupler interface with cotton swab before assembly.
	Moisture trapped within endoscope between endoscope lens optics and endoscope eyepiece.	Return to MicroAire Repair Center for repair.	Protect endoscope in its autoclave case during processing or when not in use.
Fogging— after insertion into surgical site	Condensation due to temperature difference between endoscope, SmartRelease handpiece and patient's tissue.	Attempt to warm endoscope to patient's tissue temperature: 1. Keep device inside tunnel until endoscope warms to body temperature, approximately 45 seconds. 2. Dip or wipe endoscope tip in sterile anti-fog agent and wipe dry.	Pre-warm system by connecting light source and camera before surgeon makes the skin incision. For the Eyepiece Endoscope: If there is sufficient time between processing and the skin incision, allow endoscope to air dry in its autoclave case between procedures.
	Moisture inside camera coupler and endoscope lens interface. A single drop of moisture can cause fogging at this juncture.	Disassemble and thoroughly dry endoscope lens and camera coupler interface with alcohol or anti-fog agent and sterile cotton swab.	For back-to-back cases without sufficient time between processing and the skin incision, place the SmartRelease handpiece and instruments into pan of sterile room temperature water/saline immediately following autoclaving.
	Excess fluid inside surgical site.	Soak up fluid with sterile cotton swab.	Avoid injecting anesthetics into the surgical site. Be sure endoscope is completely dry after processing.
	Moisture trapped within endoscope between endoscope lens optics and endoscope eyepiece.	Return to MicroAire Repair Center for repair.	Protect endoscope in its autoclave case during processing or when not in use.
Fuzzy or no picture	Damaged endoscope.	Return to MicroAire Repair Center for repair.	Protect endoscope in its autoclave case during processing or when not in use.

For additional information, consult the MicroAire Instructions for Use (REF: IM-STRELEASE)

Surgical Setup

Two physical considerations dictate the best surgical setup: the surgeon's orientation with respect to the video monitor and the patient's operative elbow. The surgical suite should be set up to offer the surgeon the best view of the video monitor. The surgeon should be able to easily shift his/her gaze upward from the surgical field to the video image.

The patient is positioned supine on the operating room table with the arm abducted 75–80 degrees, elbow flexed 60–90 degrees and supinated to allow visualization and access to the medial epicondyle of the elbow, retrocondylar groove, and olecranon process. The patient's hand is positioned, palm up, on a hand table equidistant between the surgical assistant and the surgeon. A tourniquet should be used in this procedure. Care should be taken to avoid pressure on the ulnar nerve at the elbow. Sterile draping leaves the distal upper arm, elbow, forearm, wrist and hand distal to the tourniquet fully exposed to permit exsanguination of the forearm and the hand. The hand, wrist, forearm, and the arm proximal to the elbow should be completely exsanguinated using an Esmark bandage.

The surgeon's hand, when holding the instrument, should naturally align the blade assembly so that it points from the retrocondylar groove parallel and superficial to the ulnar nerve. This configuration is anatomically optimal for avoiding injury to

the ulnar nerve. Surgeons using the endoscope take the axillary position when performing either a left- or right-sided cubital tunnel release. The ambidextrous surgeon may choose to use different hands for distal versus proximal release. A right-handed surgeon would simply rotate the camera 180 degrees within the blade assembly to allow serial use of the handpiece in forehand and backhand fashion. **[Figure ii]**

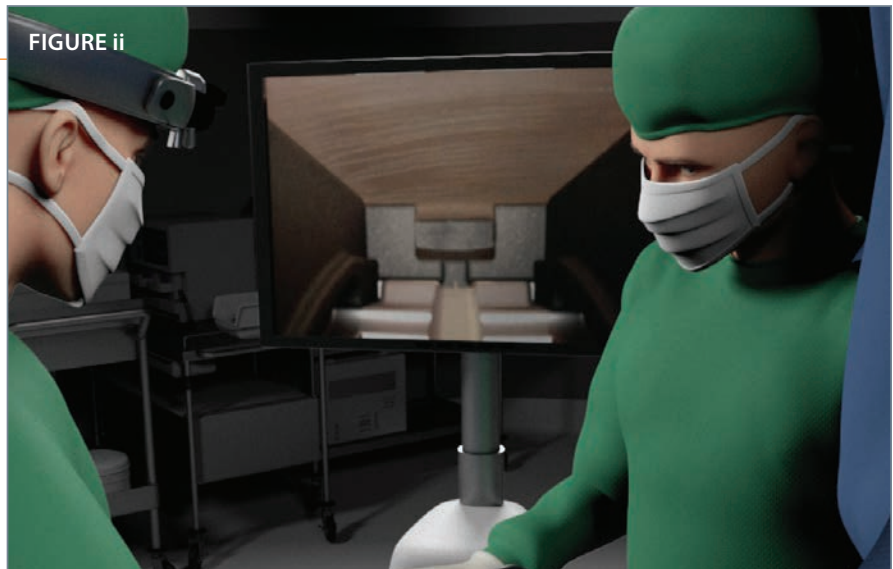To conduct a cubital tunnel release procedure using the MicroAire SmartRelease Cubital Tunnel Release System, the following equipment is recommended:

- 2 double-pronged skin hooks
- 2 Ragnell right angle retractors
- 1 pair of long, curved, blunt-tipped scissors
- 1 pair of tenotomy scissors
- 1 Sterile skin marking pen
- 2 Senn rake retractors
- 1 Adson tissue forceps with serrated tips or teeth
- 1 scalpel, #15 blade
- 1 Aufricht Retractor
- 1 pair curved blunt-tipped scissors
- MicroAire SmartRelease instruments

IMPORTANT

In the surgical suite—before the patient is brought into surgery with the intention of performing the procedure endoscopically—the MicroAire SmartRelease Cubital Tunnel System should be fully assembled and checked for correct operation, which includes blade elevation and retraction and a clear video image. The equipment, including the instruments and the video monitor, should be positioned relative to the operating table and surgeon's position after the extremity is prepped and draped.

FIGURE ii



Operative Technique

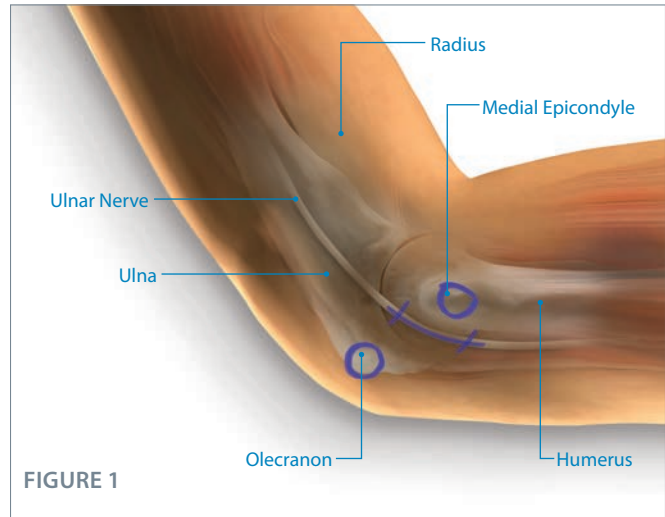
STEP 1 • Anatomical Landmarks

Before elevation of the tourniquet, it is recommended that the surgeon mark key anatomical landmarks on the patient's elbow using a sterile skin marking pen: the medial epicondyle at the elbow, the medial border of the olecranon process, and the intended longitudinal incision over the cubital groove. **[Figure 1]**

Anesthesia

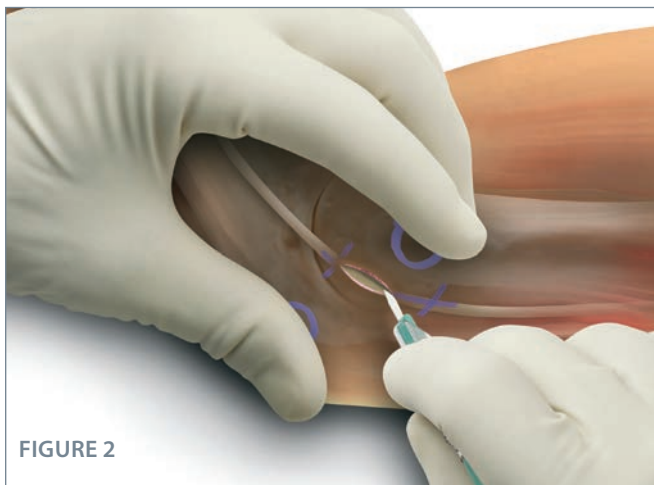A general or axillary block anesthetic is strongly recommended. Local anesthetic increases tissue fluid, which can obscure endoscopic viewing and cause lens fogging. **Only when the surgeon has gained experience with the surgical approach and instrumentation should the procedure be performed using local anesthesia with sedation.**

When local anesthesia is used, a mixture of Lidocaine and Marcaine should be injected subcutaneously from the cubital groove distally over the path of the ulnar nerve just short of the junction of the proximal and middle thirds of the forearm and proximally over the path of the ulnar nerve just short of the junction of the distal and middle thirds of the arm. Avoid injecting local anesthesia into the tunnel as it will compromise the endoscopic view.



IMPORTANT

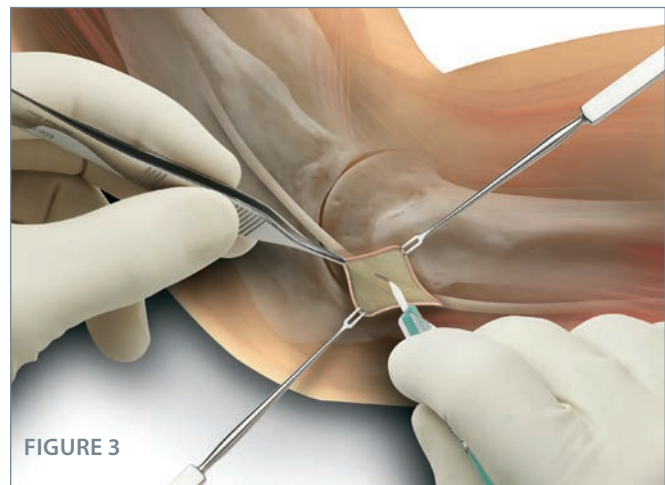
To help minimize the opportunity for patient injury under local anesthesia, it is very important that: 1) The surgeon and assistant be prepared to manually restrain any sudden movements by the patient; and 2) The instruments (i.e. elevator, scissors and blade assembly) should be passed down the cubital tunnel in a manner that will help avoid injury to the ulnar nerve and surrounding structures if the patient moves suddenly.



STEP 2 • Making the Incision

Make a 2–3 cm longitudinal incision over the cubital groove overlying the ulnar nerve, if palpable. If the ulnar nerve is not readily palpable, the incision can be made longitudinally just posterior to the medial epicondyle. **[Figure 2]**

Take care to stop short of the subcutaneous tissue which contains the cutaneous nerves. Use blunt dissection to expose the roof of the cubital tunnel. For patients with epitrochleoanconeus muscle attachments over the cubital tunnel, the muscle should be divided first. The muscle should be completely divided to expose the fascia overlying the ulnar nerve.



STEP 3 • Making the Incision, Continued

Using forceps to elevate the cubital tunnel fascia from the underlying ulnar nerve, a small longitudinal incision should be made through the fascia with a scalpel. **[Figure 3]**

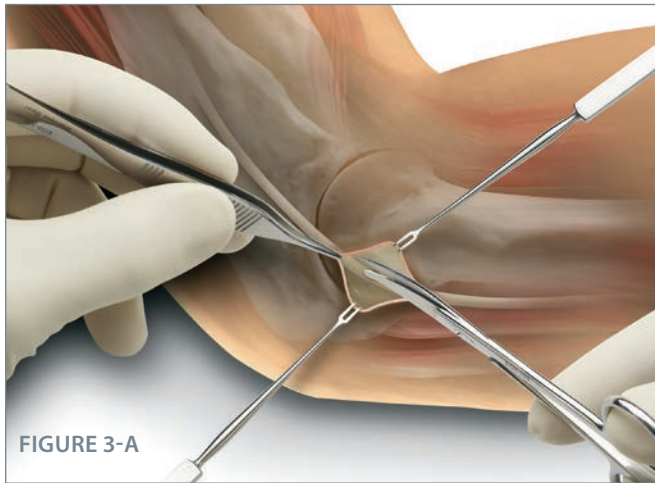


FIGURE 3-A

STEP 3-A · Making the Incision, Continued

Then extend the fascial incision 1 cm proximally and distally with tenotomy scissors to expose the underlying ulnar nerve.

[Figure 3-A]

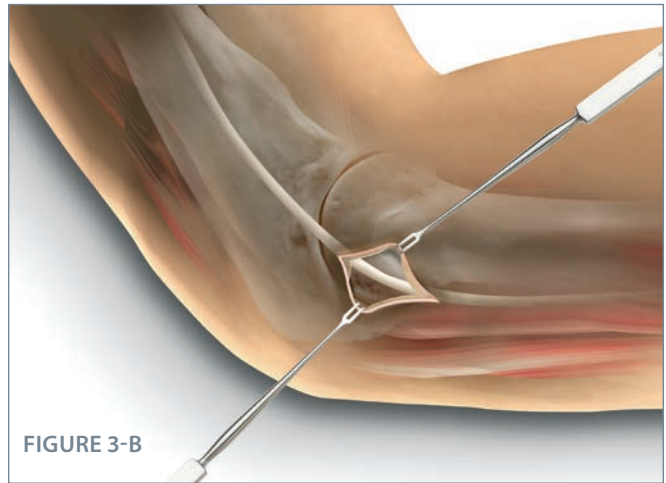


FIGURE 3-B

STEP 3-B · Making the Incision, Continued

Elevating the cubital tunnel fascia from the underlying ulnar nerve allows for the creation of a plane between the epineurium and the undersurface of the overlying fascia.

[Figure 3-B]

CAUTION

Avoid manipulation or pressure on the ulnar nerve which may result in further injury to the ulnar nerve.

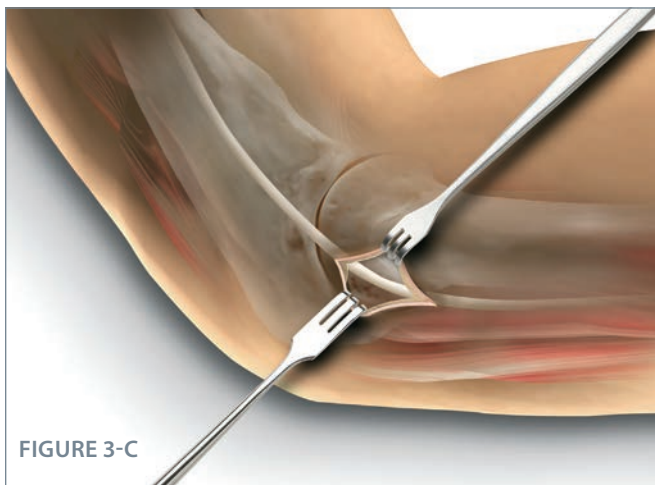


FIGURE 3-C

STEP 3-C · Preparing a Path for the Instrument

Exposure of the underlying ulnar nerve completed. **[Figure 3-C]**

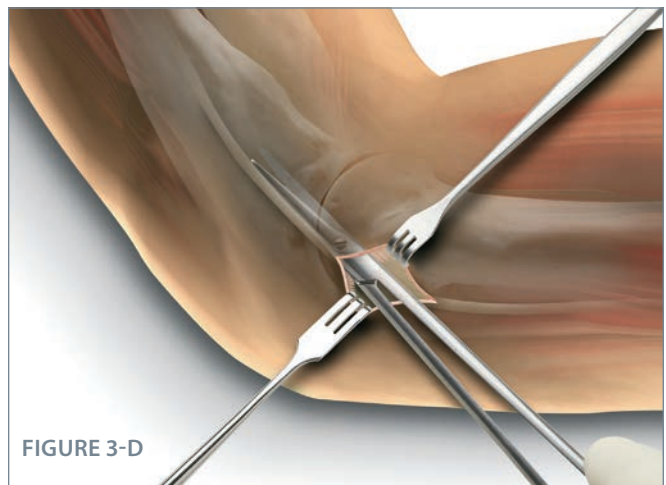


FIGURE 3-D

STEP 3-D · Preparing a Path for the Instrument, Continued

Create a subcutaneous tunnel distally and proximally to expose the fascia using a pair of long, curved, blunt-tipped scissors.

[Figure 3-D]

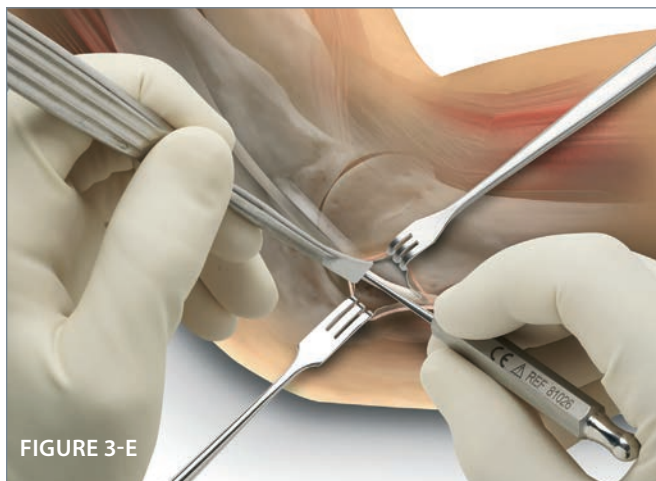

FIGURE 3-E

STEP 3-E · Preparing a Path for the Instrument, Continued

Position the elevator deep to the fascia in line with the ulnar nerve in a proximal direction. Gently pass the dilator proximally and distally deep to the fascia and superficial to the ulnar nerve to create a path for the blade assembly. **[Figure 3-E]**

NOTE: To optimally orient the elevator with the undersurface of the fascia, it is recommended that the surgeon use a retractor to elevate the subcutaneous tissues with the opposite (non-instrument) hand. The position of the patient's elbow in the flexion-extension plane can be adjusted.

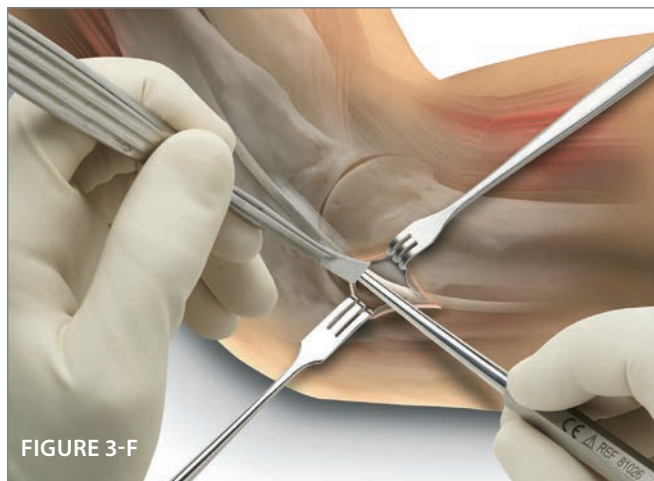

FIGURE 3-F

STEP 3-F · Preparing a Path for the Instrument, Continued

One or two passes with the elevator followed by the small dilator is sufficient to create a path proximally and distally.

[Figure 3-F]

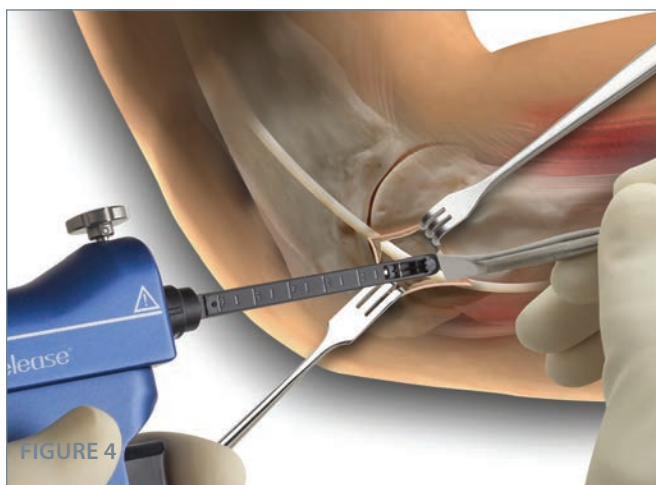


FIGURE 4

STEP 4 · Introducing the Blade Assembly Into the Cubital Tunnel

NOTE: Blade elevation and retraction should be checked before insertion into the patient's arm.

While holding the patient's arm in an externally rotated position and moderately flexing the elbow, insert the retractor proximally to elevate the subcutaneous tissue which contains the cutaneous nerves. Insert the blade assembly into the subfascial plane and advance the blade assembly proximally while viewing the transverse fibers of the fascia. Be sure to aim the blade assembly parallel and medial to the ulnar nerve while hugging the undersurface of the fascia. **[Figure 4]**

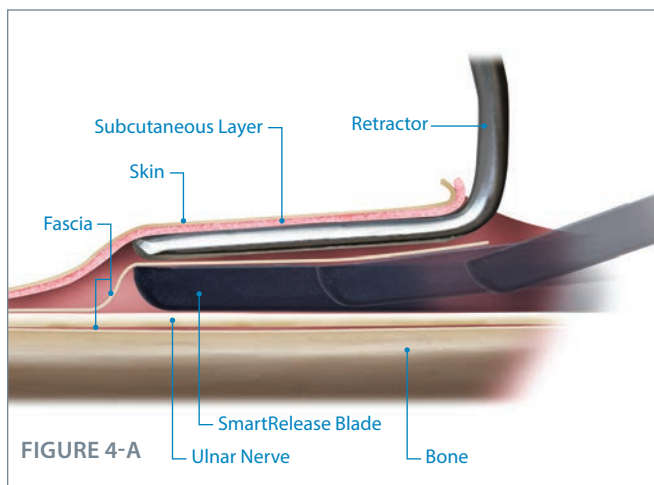


FIGURE 4-A

STEP 4-A · Introducing the Blade Assembly Into the Cubital Tunnel, Continued

Diagram showing elevation of the subcutaneous tissues while inserting the blade assembly into the subfascial plane.

[Figure 4-A]

NOTE: An unclear image may indicate fogging. Please refer to the Troubleshooting section on page 4.




FIGURE 5

STEP 5 • Release the Proximal Fascia

Once assured that only fascia can be viewed, [Figure 5] elevate the blade so that it engages the proximal extent of the fascia to be divided while pressing firmly up against the fascia and elevating the subcutaneous tissue with a retractor. Firmly but gently withdraw the blade assembly to divide the proximal fascia, except for the most distal 1 cm of the fascia. This will allow the surgeon to reinsert the blade assembly easily to inspect the divided fascia proximally. Once the surgeon is satisfied with the division of the proximal fibers, the remaining distal fascia can be divided.

NOTE: The surgeon may choose to release the fascia in a single pass; however, there are advantages to releasing the fascia in serial stages (from proximal to distal).




FIGURE 5-A

STEP 5-A • Release the Proximal Fascia

NOTE: Subcutaneous tissue lies superficial to the upper arm fascia. Leaving the distal portion of the ligament intact on the first pass prevents this fat from prolapsing onto the wound. This prolapsed fat can compromise the path available for reinserting the blade assembly and can interfere with visualizing the completeness of the fascial release.

1. Aim parallel to the ulnar nerve.
2. Elevate the subcutaneous tissues off the underlying fascia.
3. Apply upward pressure on blade assembly to keep window snug against the undersurface of the fascia.
4. Elevate blade and withdraw instrument to divide the proximal aspect of the fascia (ulnar “strip”) while maintaining steps 1–3. [Figure 5-A]

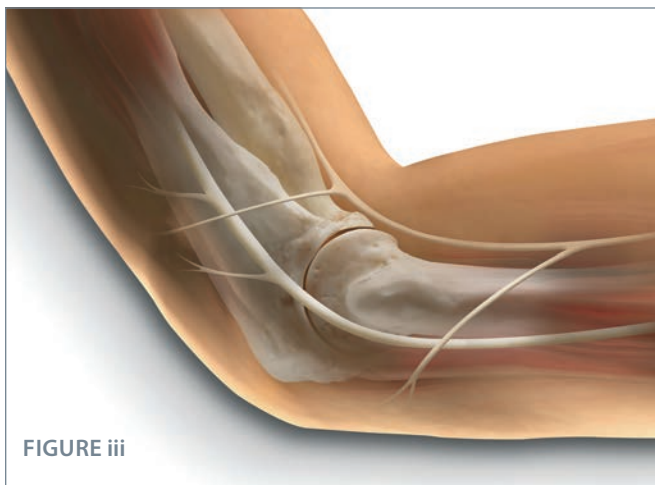


FIGURE iii

The Medial Antebrachial Nerve Branches

NOTE: The medial antebrachial cutaneous nerve branches cross at approximately 1.5 and 3.5 cm proximal and distal to the medial epicondyle, respectively. A good double check: When engaging the blade assembly, be sure the subcutaneous tissues of the overlying fascia are elevated using a retractor. [Figure iii]




FIGURE 6

STEP 6 • Inspecting the Incised Fascia

Reposition the blade assembly window to check for a complete release of the proximal half of the fascia. Use partial or complete elevation of the blade to selectively divide any remaining fascial fibers. [Figure 6]




FIGURE 6-A

STEP 6-A · Inspecting the Incised Fascia, Continued

In addition to the video monitor image, assess completeness of fascia division by several means [Figure 6-A]:

- Sensing the reduced “pressure” upon the instrument when it is reinserted in the decompressed path.
- Noting the more subcutaneous course of the blade assembly after division.
- Noting the divided fascial margins with protrusion of subcutaneous fat.

If the blade fails to retract after the trigger is released, follow these steps for safe removal:

1. Release the blade lock screw while supporting the handpiece. Use the scope to view the blade to ensure blade retraction.
2. If the blade remains elevated, carefully separate the blade assembly from the handpiece, leaving the blade assembly in place. Use the endoscope to view the blade position as the handpiece is removed from the blade assembly. The blade assembly is left in place.
3. If the blade has not returned to a retracted position, do not remove the blade assembly from the patient through the endoscopic portal. Convert to an open procedure to remove the blade assembly. Inspect the blade assembly to make sure no parts are missing. If a part is missing, take an x-ray of the patient’s elbow to ensure there are no retained metallic fragments.




FIGURE 7-A

STEP 7-A · Assessment of Adequate Release

The blade assembly can be reintroduced proximally and distally to assess complete release of the fascia. [Figure 7-A]

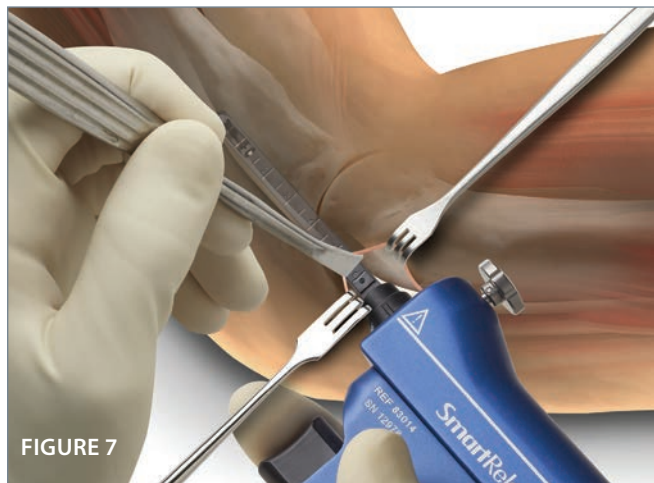


FIGURE 7

STEP 7 · Releasing the Forearm Fascia

Similar to the division of the upper arm fascia, the forearm fascia is divided in serial stages. With the subcutaneous tissue elevated, insert the blade assembly and inspect the fascia to ensure that there are no structures crossing the fascia. The most distal part of the fascia with the overlying muscles should be divided first, followed by the division of the more proximal fascia, leaving the most proximal 1 cm of the fascia uncut. This will allow for reinsertion of the blade assembly to inspect the distal fascia. Once the surgeon is satisfied with the division of the distal fibers, the remaining 1 cm of the proximal fascia can be divided. The blade assembly should then be slowly removed while any remaining visualized fascia exposed should be divided. [Figure 7]

NOTE: Serial and continuous alertness to the position of the ulnar nerve and its branches is mandatory. Inability to obtain adequate clearance of nerve branches should be addressed with conversion to an open technique. Once the fascia has been adequately released the blade assembly is removed.

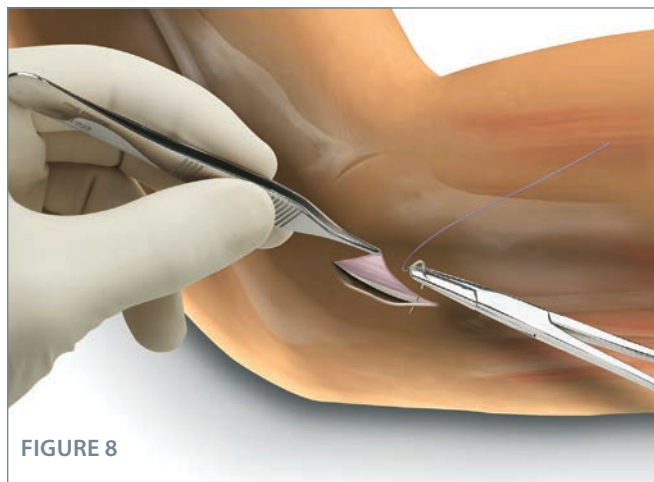


FIGURE 8

STEP 8 · Closing and Dressing the Wound

Prior to closure, irrigate the wound with saline. Infiltrate the subcutaneous tissue with 0.5% Marcaine. The method of closure should be at the preference of the surgeon and should be performed adequately to minimize the risk of dehiscence. Following wound closure, dress the elbow with nonadherent dressing, dry padding, and noncompressive circumferential wrap. Splinting is not necessary. [Figure 8]

SmartRelease® Ordering Information

System Components

83014	SmartRelease® Aluminum Handpiece
81025	2.9mm Eyepiece Autoclavable Endoscope
81026	Dilator - Small
81027	Dilator - Medium
81029	Elevator
81061	Coequal to Standard Blade Assembly
83061	Coequal to Onyx™ Blade Assembly
83040	Instrument Sterilization Tray

Refurbished Endoscopes*

81025A	Refurbished 2.9mm Eyepiece Autoclavable Endoscope
---------------	---

* Refurbished endoscopes are sold only with a core scope exchange.

Disposable Blades

81010-1	Disposable Standard Blade Assembly (Single Pack)
81010-6	Disposable Standard Blade Assembly (Six Pack)
83030-1	Disposable Onyx™ Blade Assembly (Single Pack)
83030-6	Disposable Onyx™ Blade Assembly (Six Pack)

Parts & Accessories

81151	Endoscope Light Post Adapter, Storz®/Olympus® fitting
81152	Endoscope Light Post Adapter, Wolf®/Dyonics® fitting

Storz® Registered Trademark of KARL STORZ GmbH & Co.
Olympus® Registered Trademark of Olympus America Inc.
Wolf® Registered Trademark of Richard Wolf Medical Instruments Corporation
Dyonics® Registered Trademark of Smith & Nephew



MicroAire Surgical Instruments
3590 Grand Forks Boulevard
Charlottesville, VA 22911 USA
800 722 0822 or +434 975 8000
www.microaire.com

© 2021 MicroAire Surgical Instruments, LLC
All rights reserved. LIT-CUBITAL TUNNEL-TECH REV D