# SmartRelease®

## Endoscopic Carpal Tunnel Release (ECTR)

MICROAIRE®

*For Surgery. For Life.™*

Hand Anatomy and Technical Hints

# Hand Anatomy

## Hand Topography

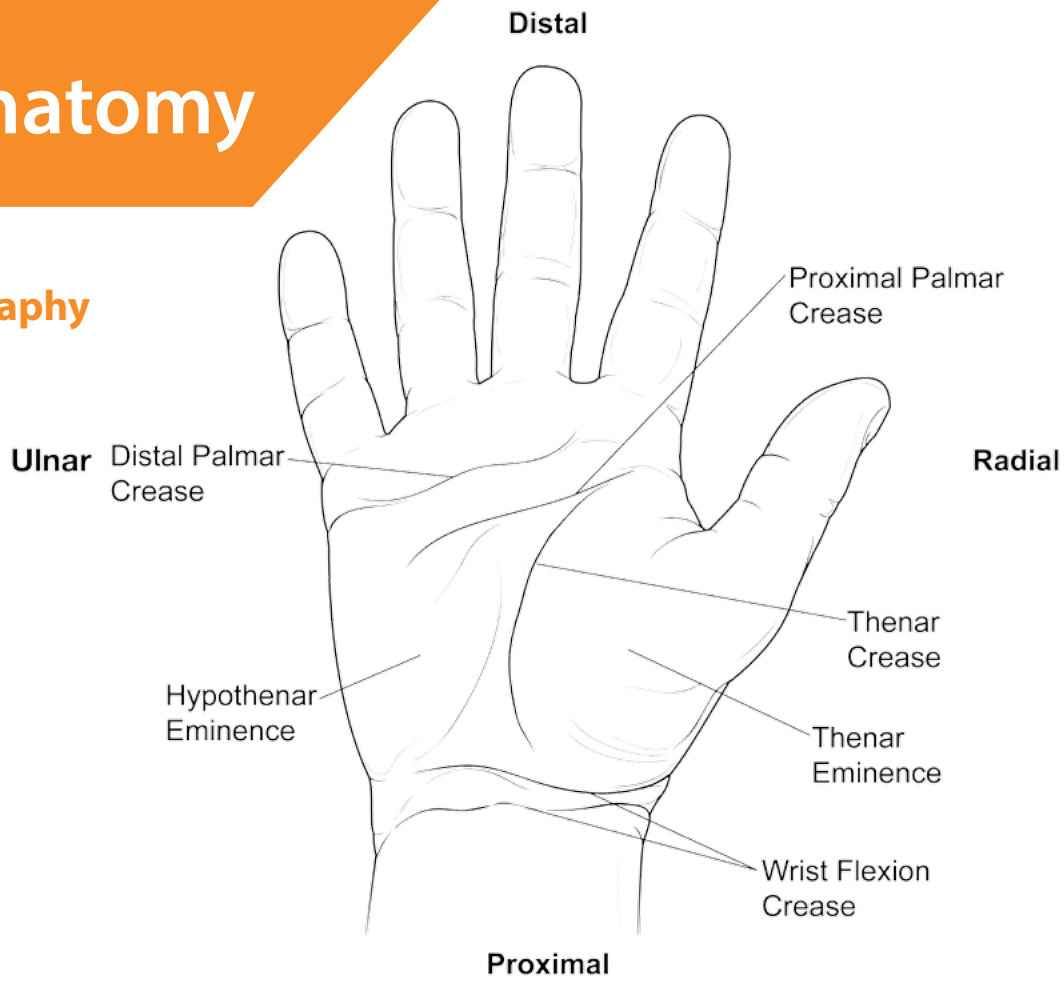


## Hand Anatomical Landmarks

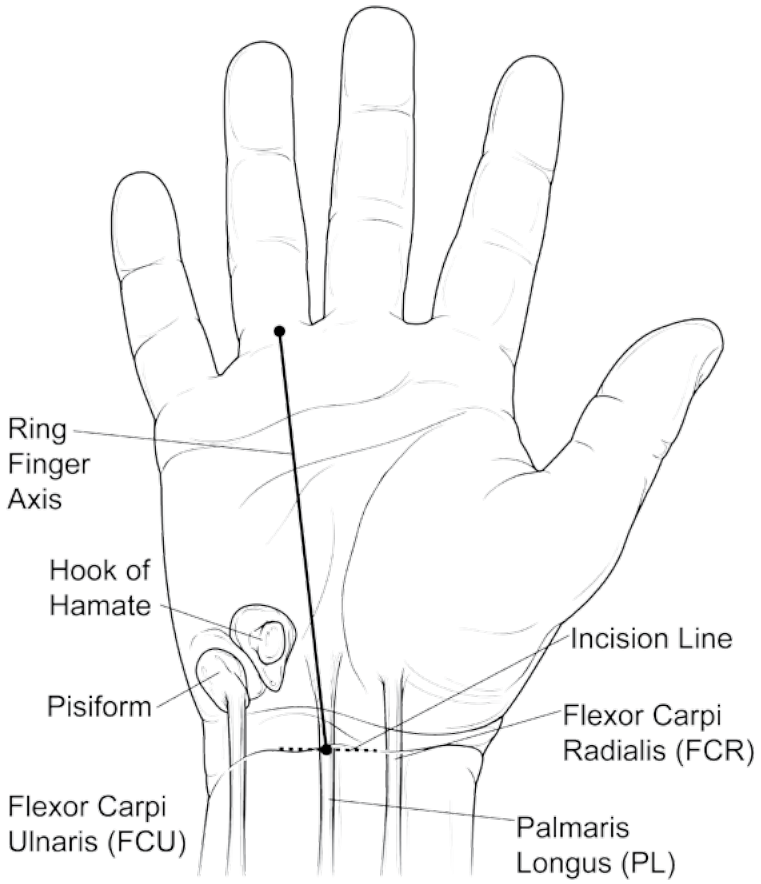

## Cobb's Line

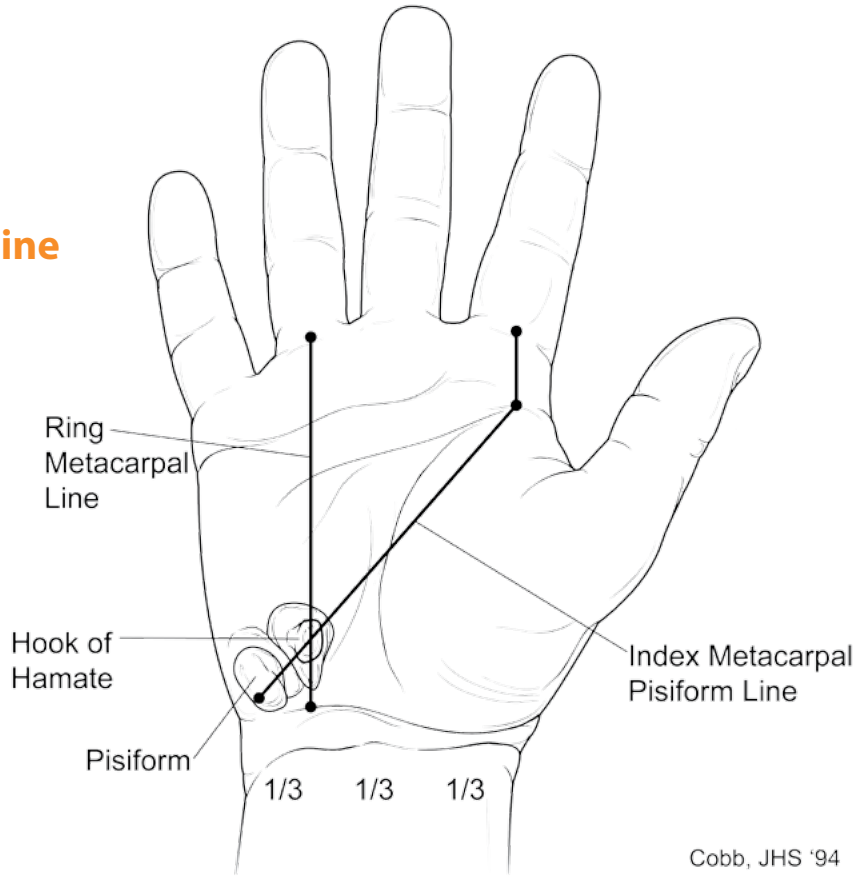


## Cardinal Line

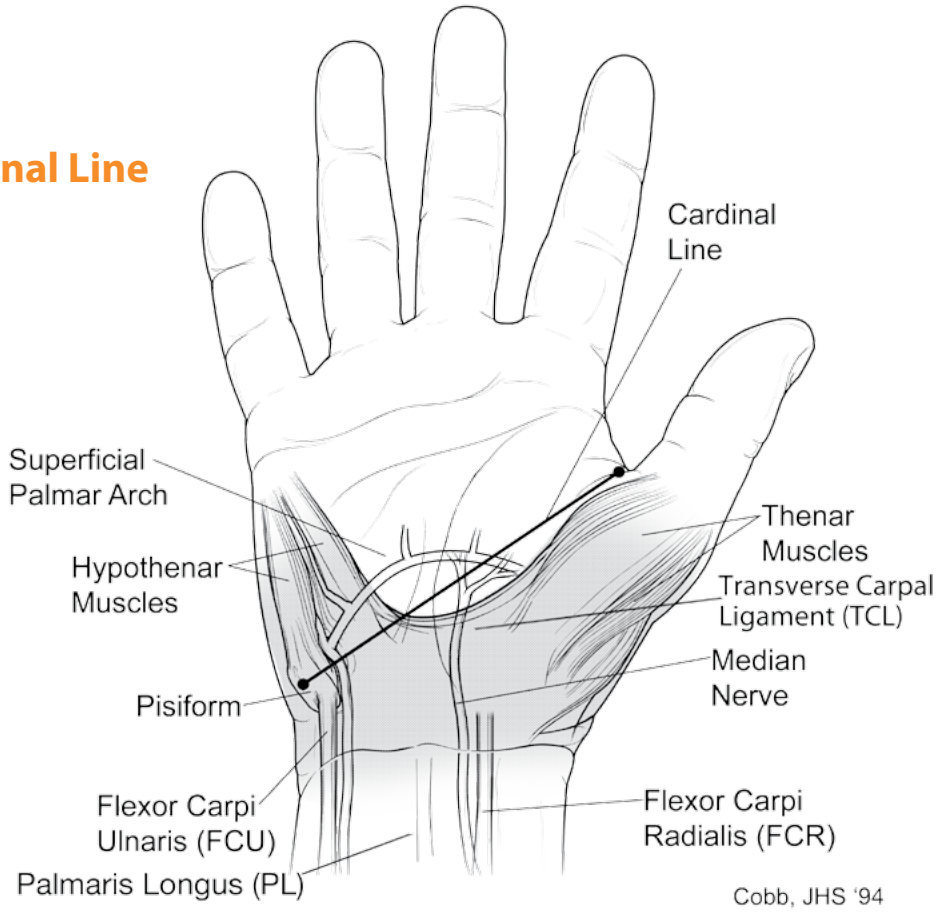

## **Wrist Cross Section with Device** (Left Hand)

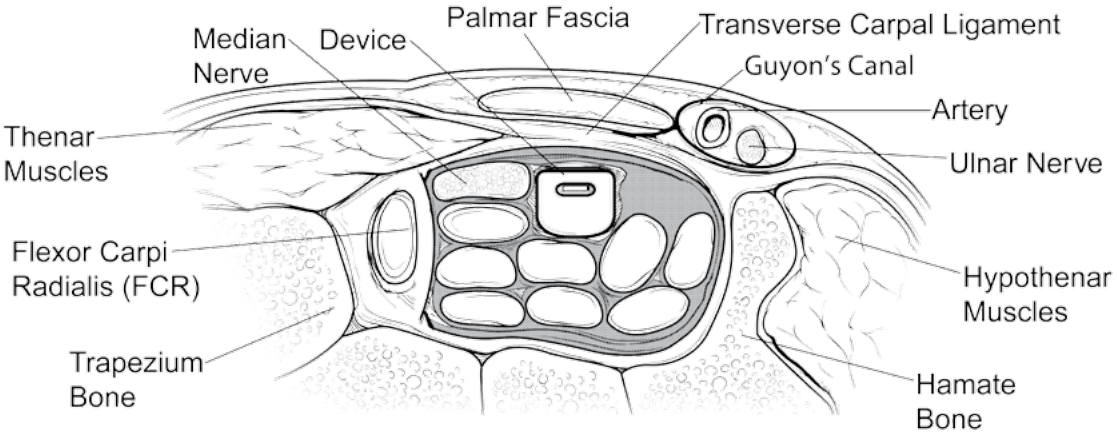


## Anatomy Identification in Cadaver Dissection

Create a wrist incision as described in the *MicroAire SmartRelease Surgical Technique (LIT-ECTR-TECH).*

Incise the skin and palmar fascia from the proximal transverse palmar crease to the insertion point in the wrist incision.

Excise the fat and remove tissue to obtain a clear view of the important structures.

Identify:

- Median nerve
- Thenar motor branch
- Common digital nerve to the third and fourth web
- Branch of ulnar nerve communicating with median nerve
- Guyon's canal and ulnar neurovascular bundle
- Superficial palmar arterial arch

Place the blade assembly in the proper position to cut the TCL and observe the relationship between the blade assembly and:

- The main trunk of the median nerve
- The common digital nerve to third and fourth finger web
- Guyon's canal
- The superficial branch of ulnar artery

# **Ten Rules** to Follow When Using the MicroAire Carpal Tunnel Release System

*By Edward North, M.D.*

## #1 Know Your Anatomy.

This device is not the same as an arthroscope. Many critical structures lie within 1 or 2 mm of the cutting blade. The safe area for ligament transaction is in line with the ring finger.

## #2 Never, Never Overcommit Yourself.

Despite your enthusiasm with this new technique, don't promise the patient an endoscopic release. Technical problems or anatomical abnormalities may prevent endoscopic carpal tunnel release. Your patients should be informed at the pre-op visit that the incidence of conversion to open procedure for their safety is around 5%.

## #3 Make Certain the Equipment is Working Properly Before You Begin.

The light source should be on, a clear image obtained, focus and whiteness adjustment made, the lens defogged, and the blade assembly well secured and properly aligned. This will lessen the chance of technical problems that will obscure your vision which could increase the risk of injury to critical structures.

## #4 If the Scope Insertion is Obstructed, Abort.

You cannot see the source of obstruction through the scope and it could be an aberrant branch of the median nerve. To force the blade assembly into the canal could cause injury to such a nerve branch. Convert to an open procedure if this occurs.

## #5 Be Certain You Are in the Carpal Canal *(or you had better not be in the loge of Guyon)*.

This is when damage to the ulnar nerve occurs. Make your initial window through the forearm fascia beneath the palmaris longus tendon and look for the median nerve beneath the fascia. If you begin your skin incision in one of the more proximal volar wrist creases, it is easier to differentiate the vulgar carpal ligament covering Guyon's canal from the transverse carpal ligament covering the carpal tunnel (although this skin approach leaves a less cosmetic scar).

## #6 If You Can't See Well, Abort.

Nothing will get you into trouble faster than proceeding with division of the ligament without a clear view of the transverse fibers of the ligament. You may have tenosynovium interposed or you may be on the dorsal surface of the median nerve. You absolutely must see the transverse ligament fibers along a strip the entire length of the canal before cutting.

## #7 Do Not Explore the Carpal Canal with the Scope.

In the first place, you can't see anything because the soft tissues collapse over the window and you cannot get far enough away to see things like a median nerve constriction. Secondly, you may cause a neurapraxia or get into the wrong plane by manipulating the scope around the canal. The blade assembly is a retractor used 1) to visualize the ligament to be cut and 2) to exclude the other critical structures.

## #8 If the View is Not Normal, Abort.

There may be unusual anatomy that will prevent clear visualization of the ligament. Or, more commonly, there may be a clear distal demarcation of the ligament due to prolongation of fibers of the palmar fascia. Rather than cutting more distally with the blade assembly, thereby risking injury to the superficial vascular arch and the common digital nerves, convert to an open procedure.

## #9 Stay in Line with the Ring Finger.

Draw a line on the skin and stay along this line in your preparation of the pathway and cutting. This will keep you between the ulnar and median nerves. Since the scope pivots on the hook of the hamate, moving the handle slightly out of line with the ring finger can cause the tip of the blade assembly to swing more out of line with the ring finger.

## #10 When in Doubt, Get Out.

If for any reason, either as described above or a problem not yet reported, you are uncomfortable proceeding, convert to an open release. The morbidity with an open procedure will be much less than with a severed nerve.

# **Technical Hints** on Performing ECTR Using the MicroAire Carpal Tunnel Release System

*By Edward Diao, M.D. Chief, Hand and Microsurgery Service, University of California, San Francisco*

1. Make sure you're down to the right level. Do not be fooled by dissecting subcutaneous fat. The ante brachial fascia and flexor retinaculum should be a discrete structure, below the level of the subcutaneous vessels, and if a palmaris longus is present, directly deep to that structure. If you have achieved the proper level, there should be fascial layer which is visible.

2. Make the U-shaped flap wide enough to not impinge upon the nosepiece of the endoscopic carpal tunnel device.

3. Use the synovial elevator carefully, but adequately to palpate the transverse striations on the undersurface of the transverse carpal ligament and to remove some of the synovium away from this layer, for better visualization.

4. Make sure you're not in Guyon's canal. If you're in Guyon's canal, the hamate finder or endoscopic device will be subcutaneously palpable, at the proximal one-third of the palm. If, however, you're in the carpal tunnel canal, the device will not be palpable in the proximal one-third of the palm, but will "re-emerge" at the level of the distal edge of transverse carpal ligament at the junction of the middle and proximal one-third, at or about the level of Kaplan's line.

5. Use bimanual palpation. This is an important guide.

6. Be aware of the axis of the ring finger as your aiming point.

7. Use transillumination, and the difference between the quality of the light as you are passing from underneath the transverse carpal ligament, into the mid-palmar area.

8. Consider rolling the endoscopic carpal tunnel device radially to visualize the median nerve and flexor tendons, and to see how much of a "safe zone" you have in the undersurface of the transverse carpal ligament.

9. If you perform a partial division of the transverse carpal ligament and the fat is prolapsing from the palmar layers through the cut transverse carpal ligament to obscure your visualization, use a Senn or Ragnell retractor to hold up the fat, at the level of the partially cut transverse carpal ligament. Then you can visualize things well, to perform the remainder of the transverse carpal ligament division.

   This technique can be used to release the proximal portions, while saving the division of the distal-most portion of the transverse carpal ligament for a "second pass". One can alternatively use Dr. Richard Tortsa's suggestion of releasing the distal one-third to one-half of the ligament first, then doing the proximal portion in the second pass.

10. If you have completely divided the transverse carpal ligament, you should not be able to visualize both cut leaflets of the cut transverse carpal ligament simultaneously (see *MicroAire SmartRelease Surgical Technique (LIT-ECTR-TECH)* for reference).

# **Points to Consider** in the MicroAire Carpal Tunnel Release System Surgical Skills Workshop

*From the MicroAire SmartRelease Surgical Technique (LIT-ECTR-TECH)*

1. If you can't see, don't cut. Be sure you and your patient are prepared to abandon the procedure in favor of an open carpal tunnel release.

2. Aim at the ring finger, hug the heel of the hamate, snugly apply the window to the deep side of the ligament, elevate the blade and slowly withdraw the device.

3. Review the ways to stay out of Guyon's canal: review anatomy, note that Guyon's doesn't have synovium in it.

4. Scale on nosepiece: scale is a relative guide allowing you to correlate surface anatomy with what you see in the endoscopic view. Note that scale is in centimeters and starts with point of blade elevation.

5. Control and adjust wrist position in the flexion extension plane with your opposite hand; allows surgeon to accurately use tip of disposable to sweep synovium and fat off of ligament especially distal ligament when making second and third passes. Also, this approach positions surgeon's thumb to palpate course of blade assembly to bounce on soft tissues to help define (endoscopically) how rigid remaining tissues are. In addition, you can use thumb pressure to hold tissue snugly opposed to the window.

6. Be sure to incise fascia proximal to skin incision using tenotomy scissors.

7. Goal of pre-op work up : 1) define patient with carpal tunnel syndrome of severity adequate to deserve surgical decompression, 2) by the overall clinical picture including history, physical and radiographic exam, define that there is no pathology inside the carpal tunnel that needs to be viewed or treated during surgery.

   **THIS SURGICAL SYSTEM IS DESIGNED SOLELY TO VISUALIZE AND CUT THE TRANSVERSE CARPAL LIGAMENT!**

8. Local anesthesia: Surgery can usually be performed under local anesthesia supported with sedation and other anesthetic agents as needed. You should attempt surgery under local only after you have gained experience with the operative procedure and has mastered the technical details of the surgical approach and instrumentation under block or general anesthesia.

9. The "secret to success" requires a careful surgical approach designed to define a plane between the finger flexor synovium and the deep side of the transverse carpal ligament. This surgical plane gives the surgeon a clear unobstructed view of the bundles of collagen of the ligament for their safe endoscopic division.

10. A transverse incision in a wrist flexion crease combined with an intracuticular wound closure produces a scar that is essentially invisible.

11. Post-operatively, use a splint that allows the thumb to fall into opposition. Post-op splinting that forces the thumb into extension and supination (into the plane of the palm of the hand) tends to pull the cut edges of the transverse carpal ligament apart resulting in a weak opposition and flattening of the proximal arch of the palm of the hand. Although important in endoscopic carpal tunnel release, it is critical in conventional open carpal tunnel release as the radial half of the divided transverse carpal ligament is unstable secondary to division of the overlying soft tissues (palmar fascia, etc.).

12. Pre-operative x-rays are important to rule out pathology of the bony canal, especially anomalies and non-unions of the hook of the hamate as well as calcific tendonitis. These patients deserve open carpal tunnel release.

13. Light level: the ideal endoscopic light level allows appreciation of the contour and texture of the collagen bundles of the transverse carpal ligament. Excessive lighting destroys this important definition. This is frequently achieved with manual control of the light level.

14. All instrumentation (the synovium elevator, hamate finders and blade assembly) are introduced down the ulnar side of the carpal tunnel with the wrist in some degree of extension. Care is taken to maintain a ring finger aim, hug the hook of the hamate and keep the instrumentation snugly applied to the deep side of the ligament.

15. Following endoscopic carpal tunnel release, patients should avoid power gripping, especially with the wrist flexed, until soft tissue (ligament) healing is complete.

16. Partial degrees of blade elevation are useful with second passes to release remaining bands of ligament collagen.

17. The surgical goal is to completely divide the transverse carpal ligament as defined by the creation of a trapezoidal defect in the ligament. In a patient, the two halves of the ligament typically retract approximately 5 mm to allow insertion of the blade assembly between the two cut edges of the ligament. Gentle rotation of the blade assembly from side to side will allow visualization of the cut edges of the ligament.

18. Additional cuts of soft tissues superficial to the transverse carpal ligament divide fascial layers that are important in stabilizing the origin of the thenar muscles. This results in a progressive loss of the change in morbidity gained by endoscopic carpal tunnel release.

19. Note that most cadavers lose the elastic properties of their carpal tunnel. You should note two differences between cadavers and patients: 1) the ligament is more difficult to cut in a cadaver because its fibers are under less (or no) resting tension and, 2) the divided ligament is "reluctant" to retract in a cadaver (it retracts readily in a patient).

20. If you want to get your patient back to work earlier, let them know pre-operatively about the change in morbidity achieved by endoscopic carpal tunnel release. A patient who has not experienced open carpal tunnel release on their opposite hand may not appreciate the decrease in morbidity achieved endoscopically. This helps break the post-operative disability syndrome typical of some workman comp patients. Be positive and reassuring and this will help the patient meet your expectations as well as the potential of endoscopic carpal tunnel release.

*Surgeon Recommended*

# Local Anesthesia Technique for ECTR

*By Michael J. Wheatley, M.D., Portland, Oregon*

## Equipment

- 30 gauge 1 inch needle
- 27 gauge 1.5 inch needle
- (2) 5 cc syringes
- 10 cc of 2% lidocaine with epinephrine
- 8.4% Sodium Bicarbonate

A dense median nerve block is essential for comfortable endoscopic carpal tunnel release under local anesthesia. The median nerve is located between the FCR and palmar longus tendons and can extend ulnar to the palmaris longus tendon. Therefore, safer areas for median nerve are through or radial to the FCR tendon and along the axis of the fourth ray. The use of small bore needles greatly minimizes the risk of iatrogenic median nerve injury. Local anesthesia should be administered approximately 20–30 minutes prior to the procedure to allow for a dense median nerve block. Anesthetizing the ulnar nerve is not necessary, but the transverse carpal ligament must be anesthetized with a palmar block. Median nerve block alone does not reliably anesthetize the transverse carpal ligament.

Place 1 cc of 8.4% sodium bicarbonate in 10 cc of 2% lidocaine with epinephrine. This will raise the pH of the lidocaine and significantly decrease the pain with injection.

Mark the radial aspect of the FCR tendon at a point 3 cm proximal to the wrist flexion crease. Inject ½ cc of lidocaine with epinephrine at this point using the 30-gauge needle. Then, slowly advance the needle at a 45-degree angle to the FCR tendon. When the needle is inserted to ½ of its length, injection 3 cc of the local anesthesia solution. Advance the needle to ¾ of its length and inject the remaining 2 cc of solution. Next, mark the incision site. From the initial FCR injection point, slowly advance the 27-gauge needle, injecting in the subcutaneous tissue while the needle is advanced. Once the incision is anesthetized, perforate the skin with the 27-gauge needle in the mid-portion of the anesthetized incision and then advance slowly into the palm in the area overlying the transverse carpal ligament. Inject 2–3 cc in the tissues superficial to the transverse carpal ligament.

## Alternate Technique

Mark a point 3 cm proximal to the distal wrist flexion crease along the ulnar side of the axis of the third ray. Using the 30-gauge needle angled in a 45-degree proximal and 45-degree radial direction, injection up to 8 cc at depths of ½ to ¾ the length of the needle. Mark the incision. Starting at the already anesthetized initial point, inject ½ cc of lidocaine with epinephrine into the incision area in the subcutaneous tissue using the 30-gauge needle. Once the incision is anesthetized, perforate the skin with the 27-gauge needle in the mid-portion of the anesthetized incision and then advance slowly into the palm in the area overlying the transverse carpal ligament. Inject 2–3 cc in the tissues superficial to the transverse carpal ligament.

The patient should experience paresthesias and numbness in the median nerve distribution. Additional lidocaine can be given if the block is not dense. This may be necessary in men with large hands. Ulnar nerve block is not required for comfortable local only ECTR.

MICROAIRE®
*For Surgery. For Life.™*

**MicroAire Surgical Instruments**
3590 Grand Forks Boulevard
Charlottesville, VA 22911 USA
**800 722 0822** or **+434 975 8000**
**www.microaire.com**



Colson A COLSON ASSOCIATE